

## **“What’s in a wrap?”**

Lucas Van Hoof; Filip Rega; Tom Treasure; John Pepper

**Letter to the Editor** – The Journal of Thoracic and Cardiovascular Surgery

Regarding: “The Long-term fate of ascending aorta aneurysm after wrapping versus replacement” by Kim H-H et al. <https://doi.org/10.1016/j.jtcvs.2020.12.110>

Lucas Van Hoof, MD  
Resident General Surgery, PhD Student Cardiac Surgery  
Department of Cardiac Surgery, University Hospitals Leuven, Leuven, Belgium

Filip Rega, MD, PhD  
Professor of Surgery, Cardiac Surgeon  
Department of Cardiac Surgery, University Hospitals Leuven, Leuven, Belgium

Tom Treasure, MD, MS, FRCS, FRCP  
Consultant Cardiothoracic Surgeon  
Clinical Operational Research Unit, University College London, London, UK

John Pepper, MD, MChir, FRCS, FESC  
Consultant Cardiac Surgeon  
Royal Brompton and Harefield NHS Foundation Trust, Sydney Street, London, UK

Word count, excluding Figure caption and references: 462

**Corresponding author:**

Dr Lucas Van Hoof, Department of Cardiac Surgery, University Hospitals Leuven, Herestraat 49, 3000 Leuven, Belgium, [lucasvanhoof1@gmail.com](mailto:lucasvanhoof1@gmail.com), +3216 345483.

## **“What’s in a wrap?”**

Lucas Van Hoof; Filip Rega; Tom Treasure; John Pepper

**Letter to the Editor** – The Journal of Thoracic and Cardiovascular Surgery  
Regarding: “The Long-term fate of ascending aorta aneurysm after wrapping versus replacement” by Kim H-H et al. <https://doi.org/10.1016/j.jtcvs.2020.12.110>

Lucas Van Hoof, MD  
Resident General Surgery, PhD Student Cardiac Surgery  
Department of Cardiac Surgery, University Hospitals Leuven, Leuven, Belgium

Filip Rega, MD, PhD  
Professor of Surgery, Cardiac Surgeon  
Department of Cardiac Surgery, University Hospitals Leuven, Leuven, Belgium

Tom Treasure, MD, MS, FRCS, FRCP  
Consultant Cardiothoracic Surgeon  
Clinical Operational Research Unit, University College London, London, UK

John Pepper, MD, MChir, FRCS, FESC  
Consultant Cardiac Surgeon  
Royal Brompton and Harefield NHS Foundation Trust, Sydney Street, London, UK

Word count, excluding Figure caption and references: 462

**Corresponding author:**

Dr Lucas Van Hoof, Department of Cardiac Surgery, University Hospitals Leuven, Herestraat 49, 3000 Leuven, Belgium, [lucasvanhoof1@gmail.com](mailto:lucasvanhoof1@gmail.com), +3216 345483.

## **“What’s in a wrap?”**

Lucas Van Hoof; Filip Rega; Tom Treasure; John Pepper

**Letter to the Editor** – The Journal of Thoracic and Cardiovascular Surgery  
Regarding: “The Long-term fate of ascending aorta aneurysm after wrapping versus replacement” by Kim H-H et al. <https://doi.org/10.1016/j.jtcvs.2020.12.110>

Lucas Van Hoof, MD  
Resident General Surgery, PhD Student Cardiac Surgery  
Department of Cardiac Surgery, University Hospitals Leuven, Leuven, Belgium

Filip Rega, MD, PhD  
Professor of Surgery, Cardiac Surgeon  
Department of Cardiac Surgery, University Hospitals Leuven, Leuven, Belgium

Tom Treasure, MD, MS, FRCS, FRCP  
Consultant Cardiothoracic Surgeon  
Clinical Operational Research Unit, University College London, London, UK

John Pepper, MD, MChir, FRCS, FESC  
Consultant Cardiac Surgeon  
Royal Brompton and Harefield NHS Foundation Trust, Sydney Street, London, UK

Word count, excluding Figure caption and references: 462

**Corresponding author:**

Dr Lucas Van Hoof, Department of Cardiac Surgery, University Hospitals Leuven, Herestraat 49, 3000 Leuven, Belgium, [lucasvanhoof1@gmail.com](mailto:lucasvanhoof1@gmail.com), +3216 345483.

## “What’s in a wrap?”

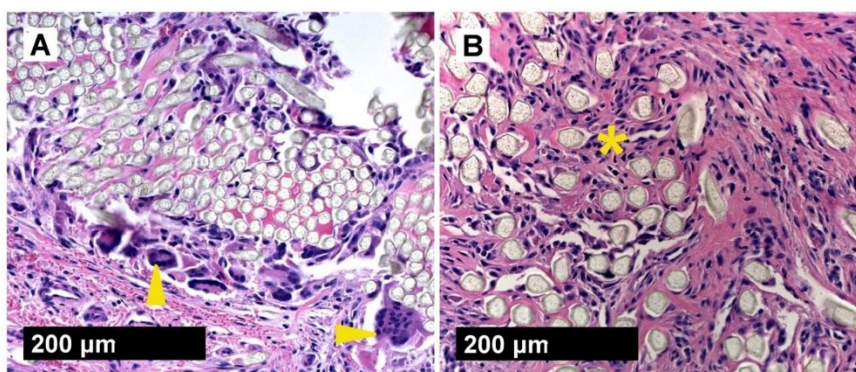
Lucas Van Hoof; Filip Rega; Tom Treasure; John Pepper.

Letter to the Editor – The Journal of Thoracic and Cardiovascular Surgery  
Regarding: “The Long-term fate of ascending aorta aneurysm after wrapping versus replacement” by Kim H-H et al. <https://doi.org/10.1016/j.jtcvs.2020.12.110>

We read with interest this retrospective, carefully analysed comparative series of 140 patients followed for a median of 7.1 years (1). At first sight, the application of a standard Hemashield® (Getinge Group, Sweden) polyethylene terephthalate (PET or Dacron®) or polytetrafluoroethylene (PTFE or Teflon®) vascular graft to wrap the ascending aorta in patients undergoing aortic valve replacement (AVR) with an ascending aortic diameter of 40-55mm sounds simple and attractive. Unfortunately, we see some concerns with the described technique.

In the aortic wrapping group there was a 14.3% incidence of “dissection/rupture” and 11.4% required re-operation on the ascending aorta or arch. This compares with an 8.6% incidence of “dissection/rupture” in the aortic replacement group with 5.7% needing re-operation. It seems that for these patients undergoing AVR, both options are unfavourable, but there is limited data on the timing, precise anatomical site or management of these adverse events.

These patients underwent surgery in a single institution and were subjected to long-term follow-up. However, it is not clear whether 2D echocardiography or 3D CT scans were used on all patients, nor is there any data on inter-observer variability. Using a linear mixed-effect model, postoperative dilatation of the aortic arch (0.343 mm/year,  $p=0.006$ ) was observed in the wrapping group. Unfortunately, no comparison with a non-operated control group can be made. Furthermore, it is not clear whether the observed arch dilatation was clinically significant, or whether the operation itself resulted in adverse events.



**Figure 1.** Cellular reaction to polymer fabrics surrounding the aorta, 20x, H&E staining. (A) Low-porosity PET vascular graft. Limited tissue ingrowth and pronounced foreign body reaction (arrowheads). (B) Macroporous PET mesh used in PEARS. Extensive incorporation with fibroblasts, collagen and neo-vessels (asterisk). (2)

The authors offer three insights into the cause of arch dilatation after ascending aortic wrapping. It was not acknowledged that microporous vascular grafts elicit limited incorporation into the vascular wall (Figure 1). By serving as a barrier, these grafts may impair the nutrition of the tunica media, leading to medial degeneration and significant weakness (2).

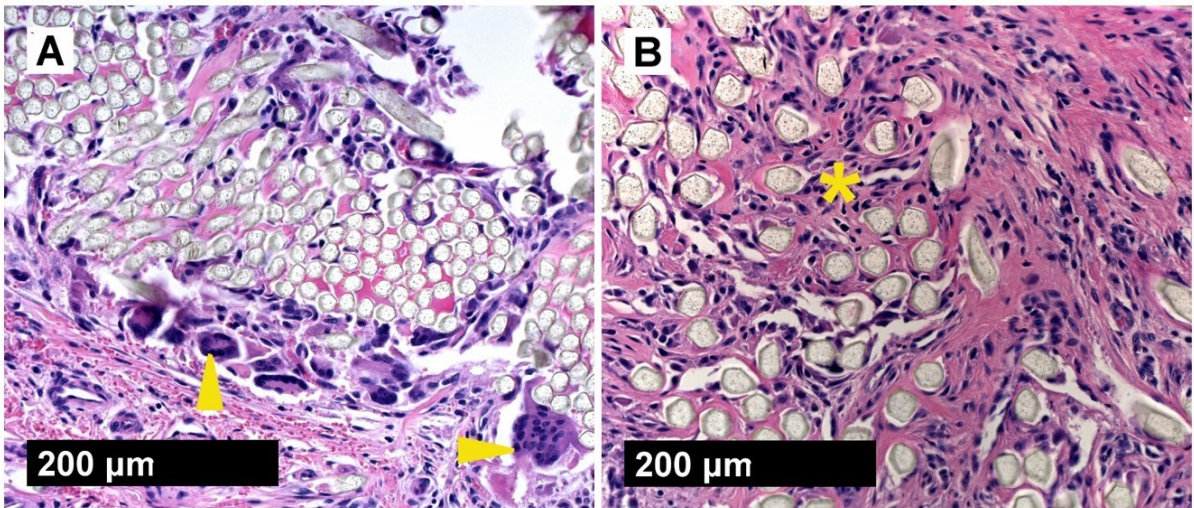
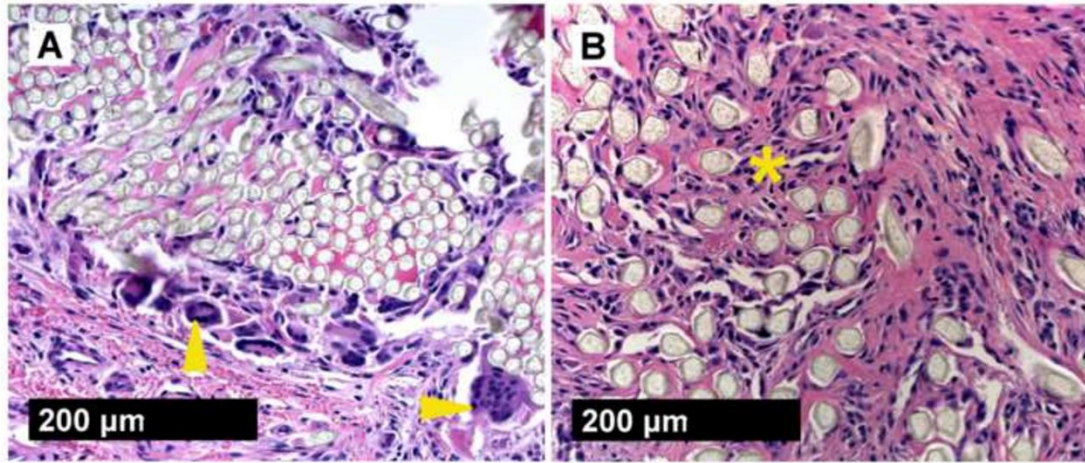
We have proposed a different approach to the prevention of aortic dissection and rupture by the use of a Personalised External Aortic Root Support (PEARS) (3). As opposed to impermeable vascular grafts, the mesh used in PEARS is macroporous with 0.7mm pores, enabling incorporation at a cellular level, thus binding the sleeve to the aortic adventitia (Figure 1) and reducing wall stress (2,4). In an interim analysis in April 2020, there were no late dissections or ruptures over 16 years of follow-up in 321 patients undergoing PEARS, consistent with previous histological and biomechanical observations (5).

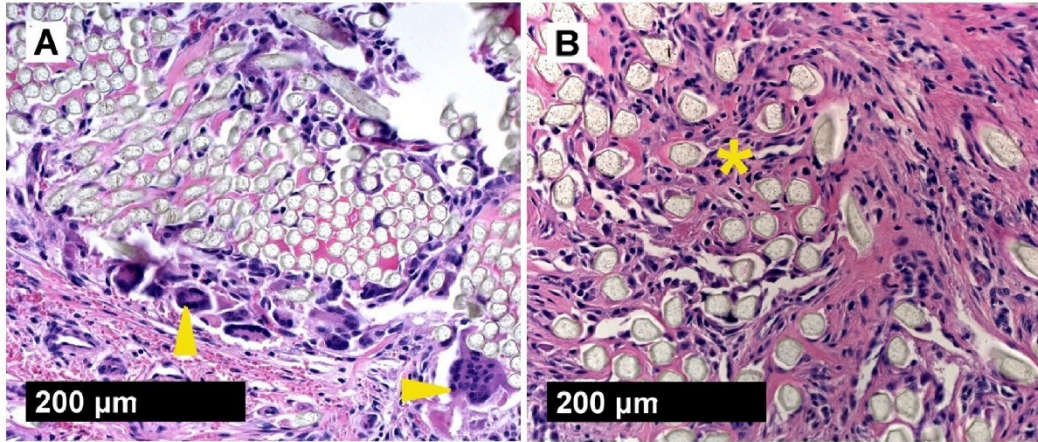
An additional feature of the PEARS sleeve is the graded reduction in hoop strength from proximal to distal as it lies around the ascending aorta. This means that, contrary to wrapping with a rigid vascular graft, there is no abrupt change in wall stress between the protected ascending aorta and the native aortic arch.

While the wrapping technique described by Kim and colleagues appears to be simple and low-cost, we identify several important points of concern in this commentary.

#### References

1. Kim H-H, Lee S, Lee SH, Youn Y-N, Yoo K-J, Joo H-C. The Long- term fate of ascending aorta aneurysm after wrapping versus replacement. *J Thorac Cardiovasc Surg.* 2021. <https://doi.org/10.1016/j.jtcvs.2020.12.110>
2. Van Hoof L, Verbrugghe P, Verbeken E, Treasure T, Famaey N, Meuris B, et al. Support of the aortic wall : a histological study in sheep comparing a macroporous mesh with low-porosity vascular graft of the same polyethylene terephthalate material. *Interact Cardiovasc Thorac Surg.* 2017;25(1):89–95.
3. Pepper J, Golesworthy T, Izgi C, Takkenberg JJM, Treasure T. Personalised external aortic root support (PEARS) to stabilise an aortic root aneurysm. *Br J Cardiol.* 2020;27:87–92.
4. Izgi C, Nyktari E, Alpendurada F, Bruengger AS, Pepper J, Treasure T, et al. Effect of personalized external aortic root support on aortic root motion and distension in Marfan syndrome patients. *Int J Cardiol.* 2015;197:154–60.
5. Nienaber CA, Yuan X, Ernst S. PEARS procedure and the difficulty to provide evidence for its benefits. *Eur Heart J.* 2020;41:4086–8.





**Figure 1.** Cellular reaction to polymer fabrics surrounding the aorta, 20x, H&E staining. (A) Low-porosity PET vascular graft. Limited tissue ingrowth and pronounced foreign body reaction (arrowheads). (B) Macroporous PET mesh used in PEARS. Extensive incorporation with fibroblasts, collagen and neo-vessels (asterisk). (Van Hoof et al ICVTS 2017).